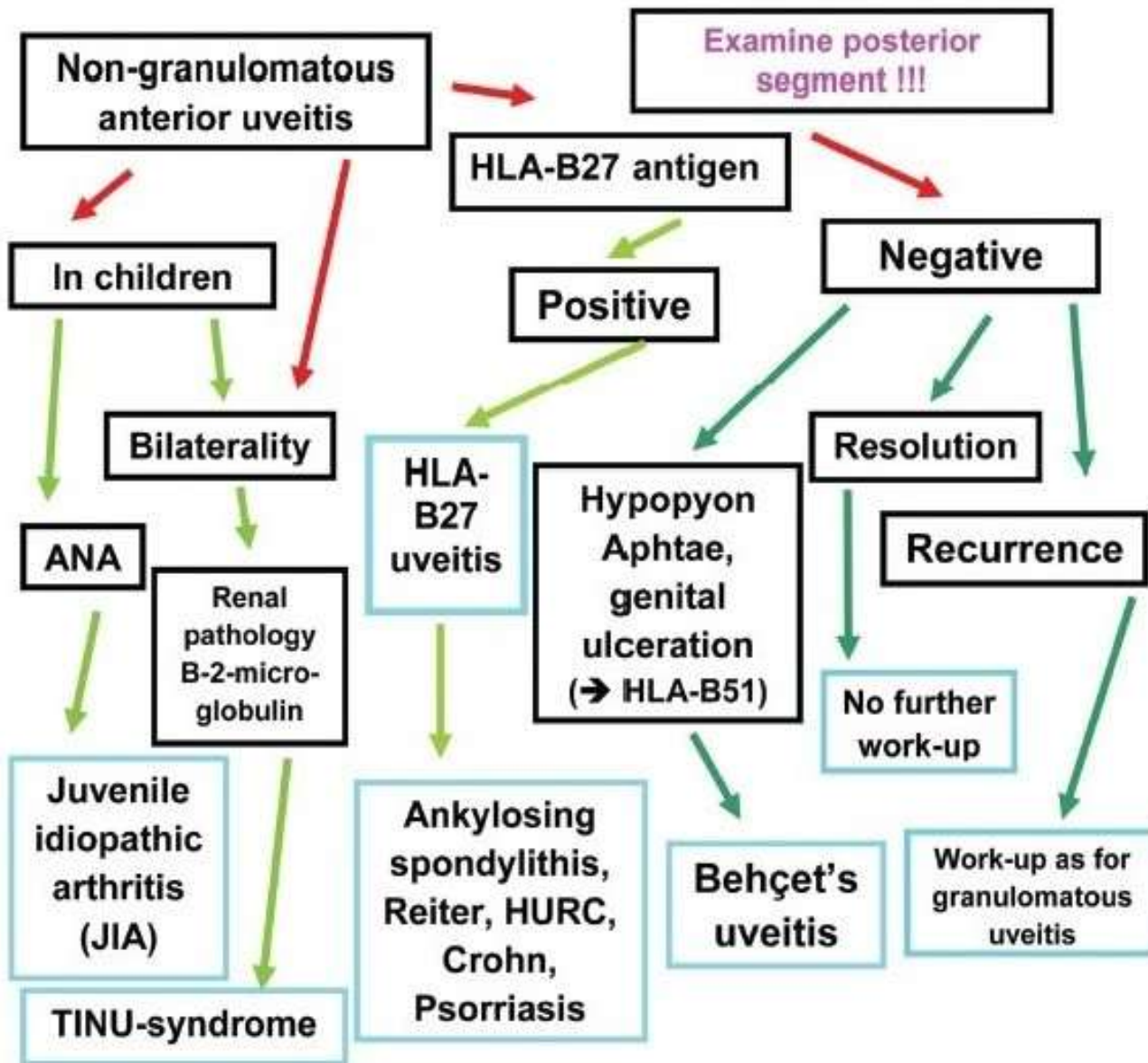


	Granulomatous	Non-granulomatous
Onset	Insidious	Acute
Keratic precipitates	<ul style="list-style-type: none"> ▪ Large, greasy ▪ Mutton-fat, white ▪ Macrophages and epithelioid cells 	<ul style="list-style-type: none"> ▪ Fine ▪ White coloured ▪ Lymphocytes and plasma cells
Iris nodules	<ul style="list-style-type: none"> ▪ Koeppe (at pupillary border) ▪ Busacca (on iris surface) 	Generally absent

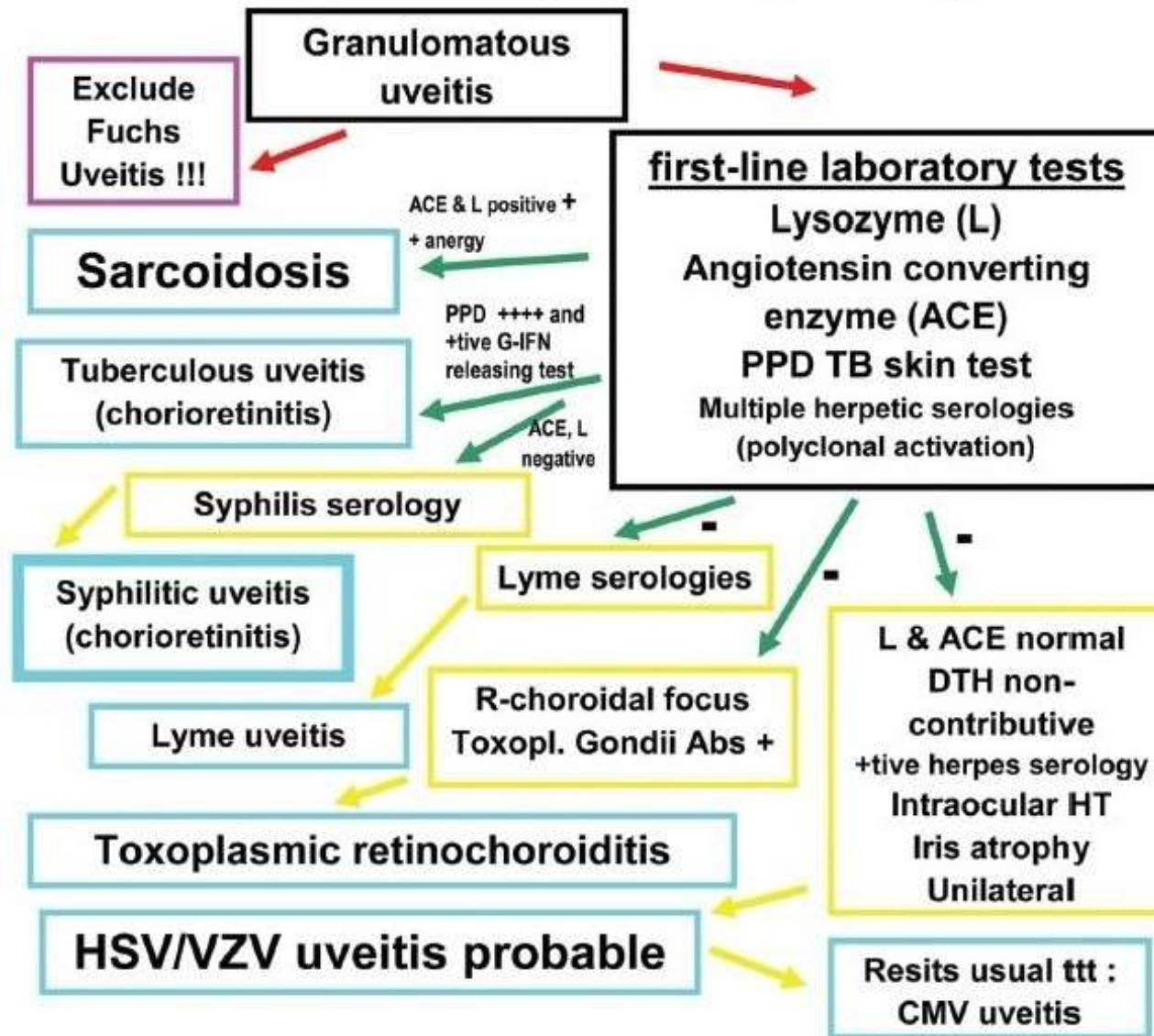
	Granulomatous	Non-granulomatous
Fundus	Choroidal nodules/granulomas	Uncommon
Course	Chronic	Maybe self limited
Posterior synechiae	Broad based	Fine
Causes	<ul style="list-style-type: none"> ▪ Suggestive of few specific conditions ▪ More commonly infectious 	<ul style="list-style-type: none"> ▪ Many anterior uveitic diseases ▪ Not helpful in formulating differential diagnosis

Diagnostic approach : non-granulomatous anterior uveitis



ANA = antinuclear antibodies ; HURC = haemorrhagic ulcerative recto-colitis; TINU = Tubulo-Interstitial nephritis and uveitis

Granulomatous uveitis : systematic diagnostic approach 2



CMV = cytomegalovirus; DTH = delayed type hypersensitivity ; G-IFN = gamma-interferon; HT = hypertension;
 TB = tuberculosis; ttt = treatment



Treatment